

How should I treat progression of disease of the jailed left anterior descending ostium after bioresorbable vascular scaffold implantation in the left circumflex?

Katsumasa Sato¹, MD; Vasileios F. Panoulas^{1,2}, MD; Toru Naganuma¹, MD; Tadashi Miyazaki¹, MD; Azeem Latib¹, MD; Antonio Colombo^{1*}, MD

1. Interventional Cardiology Unit, EMO-GVM Centro Cuore Columbus, Milan, Italy; 2. Imperial College London, National Heart and Lung Institute, London, United Kingdom

Invited experts: Ashok Seth¹, FRCP, FACC, FESC, DSc; Gaurav Mohan¹, MD, DM; Vijay Kumar¹, MD, DNB; Alexandre Abizaid², MD, PhD; J. Ribamar Costa Jr³, MD, PhD

1. Fortis Escorts Heart Institute, New Delhi, India; 2. Invasive Cardiology Department, Instituto Dante Pazzanese, São Paulo, Brazil; 3. Coronary Intervention Section, Instituto Dante Pazzanese, São Paulo, Brazil

This paper also includes accompanying supplementary data published online at: http://www.pcronline.com/asiaintervention/1st_issue/14

CASE SUMMARY

BACKGROUND: A 60-year-old male with recurrent angina (CCS class II) and equivocal exercise treadmill tests presented for elective coronary angiography. He had bioresorbable stent implantation for stable angina 12 months previously in the ostial to mid circumflex, which jailed the ostium of the left anterior descending (LAD) artery.

INVESTIGATION: Coronary angiogram, fractional flow reserve, intravascular ultrasound, optical coherence tomography.

DIAGNOSIS: Moderate distal left main disease, angiographically significant but functionally not significant LAD disease and moderate ostial circumflex disease.

MANAGEMENT: Medical therapy.

KEYWORDS: bioresorbable stent, bioresorbable vascular scaffold (BVS), fractional flow reserve (FFR), intravascular ultrasound (IVUS), scaffold

PRESENTATION OF THE CASE

A 60-year-old male re-presented with stable angina (CCS class II) and equivocal exercise treadmill test 12 months after undergoing previous elective percutaneous coronary intervention (PCI) with implantation of a bioresorbable vascular scaffold (BVS) for ostial and proximal left circumflex (LCx) lesions. Other past medical history of note included diabetes mellitus, chronic kidney disease (CKD) stage 4 and hypertension.

With regard to his index procedure, he had undergone elective PCI for CCS III stable angina with implantation of a 3.0×28 mm Absorb (Abbott Vascular, Santa Clara, CA, USA) BVS for an ostial and proximal left circumflex (LCx) lesion (**Figure 1A, Figure 1B**) with final left main stem bifurcation kissing balloon inflation (KBI). According to optical coherence tomography (OCT) findings, prior to KBI, the left anterior descending artery (LAD) orifice was jailed by BVS struts (**Figure 1C, Figure 1D**). Hence, KBI with a 3.0×20 mm non-compliant (NC) (left main coronary artery [LMCA]-LCx) and a 2.5×20 mm NC balloon (LMCA-intermediate) was performed. Though repeat OCT imaging post-KBI was not obtained due to background CKD, the final angiogram indicated an excellent result (**Figure 2A, Figure 2B, Moving image 1, Moving image 2**).

A coronary angiogram on his current admission (12 months after index procedure) showed moderate stenosis of the distal LMCA, severe stenosis of the ostial LAD and intermediate stenosis of the ostial intermediate branch (**Figure 2C, Figure 2D, Moving image 3, Moving**

*Corresponding author: EMO-GVM Centro Cuore Columbus, 48 via M. Buonarroti, 20145 Milan, Italy.

E-mail: info@emocolumbus.it

image 4), whereas the BVS in the proximal LCx was free from significant stenoses. We decided to assess the haemodynamic significance of all the aforementioned lesions and measure the minimal lumen area of the ostial LAD stenosis using fractional flow reserve (FFR) and intravascular ultrasound (IVUS), respectively. After hyperaemia, induced by intravenous administration of adenosine, FFR was measured at 0.87 in the LAD, 0.87 in the intermediate and 0.97 in the LCx. IVUS

confirmed the jailed LAD ostium from BVS struts with a minimum lumen area of 5.73 mm^2 (**Figure 3**).

In this specific patient, who was not asymptomatic, some people may suggest intervening according to the results of the coronary angiogram. However, we might be able to wait for the absorption of the BVS struts, which would theoretically lead to an increased SB ostium strut-free area. How should this patient be treated?

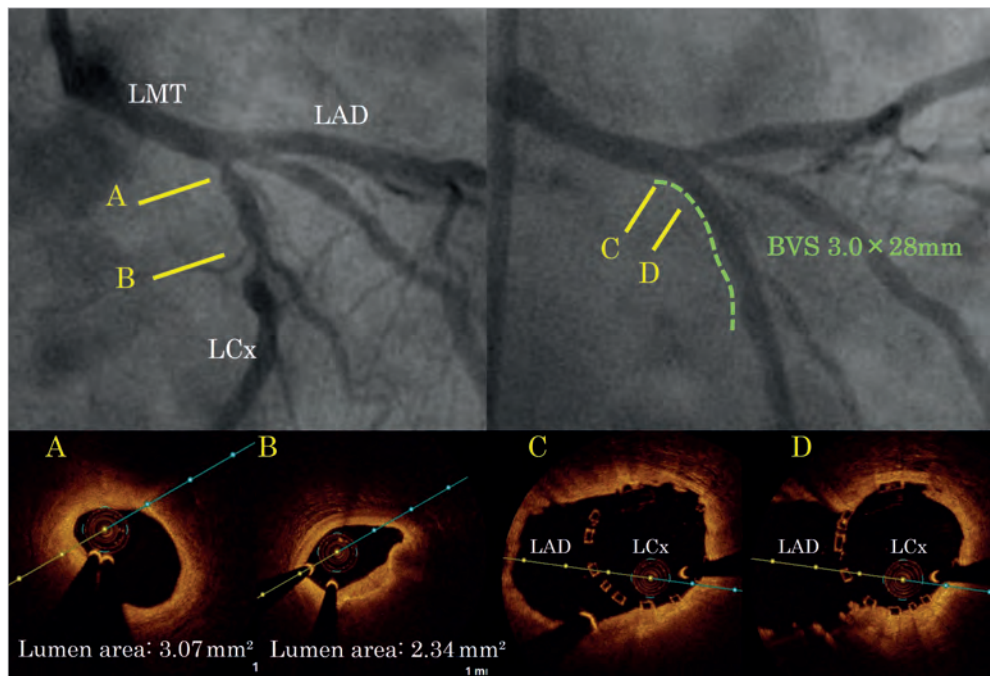


Figure 1. Index procedure angiographic and optical coherence tomography (OCT) images before and after bioresorbable vascular scaffold (BVS) implantation. Pre-procedural angiogram (left), and angiogram after BVS implantation (right). OCT demonstrated lumen area of 3.07 mm^2 in the ostial LCx (A) and a minimum lumen area of 2.34 mm^2 in the mid LCx site (B). The left anterior descending artery (LAD) orifice was jailed by the BVS struts (C, D).

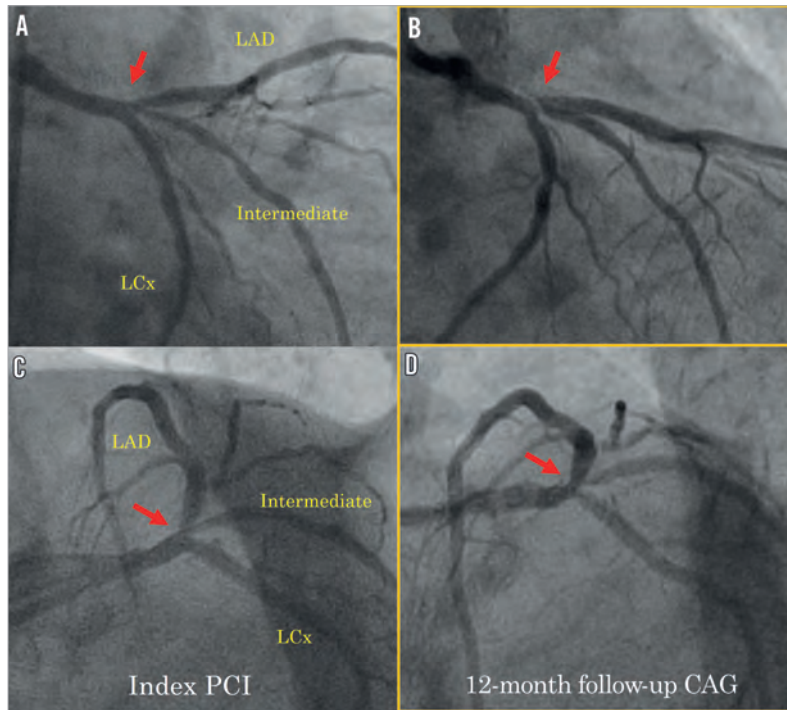


Figure 2. Comparison between index PCI post-procedural and 12-month follow-up coronary angiogram. Red arrows indicate the left anterior descending artery (LAD) lesion site. (A & C: right anterior oblique caudal view; B & D: left anterior oblique caudal view).

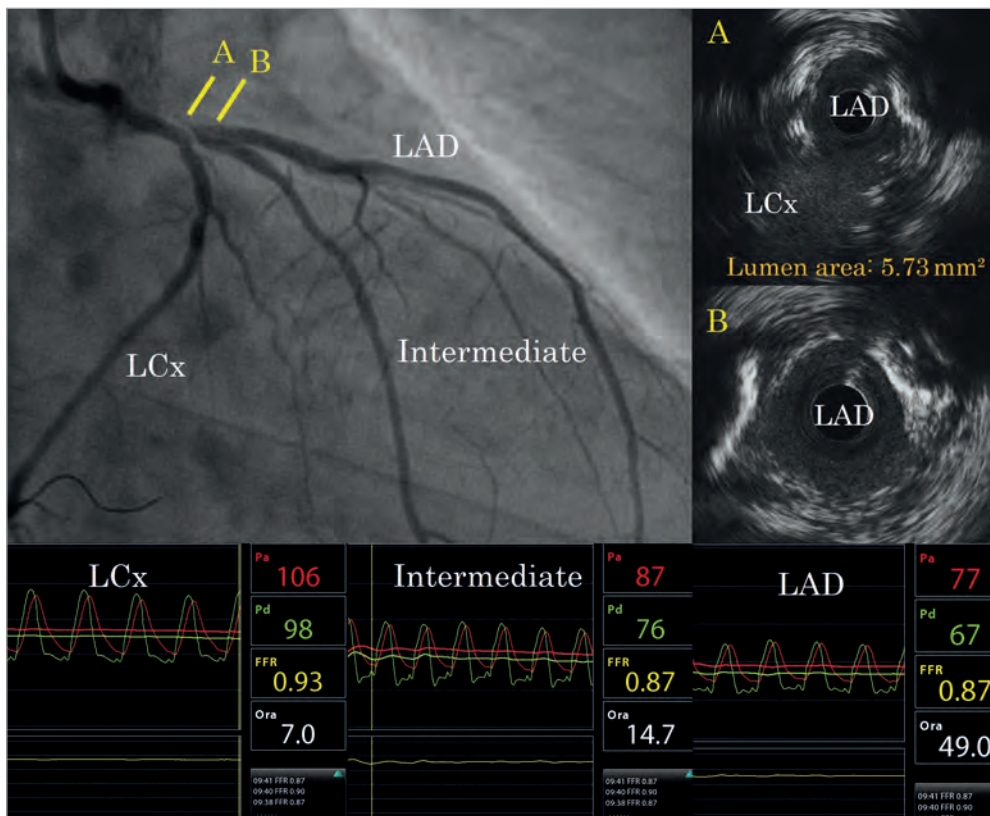


Figure 3. The results of FFR and IVUS measurements. FFR value was 0.87 in the left anterior descending (LAD) and intermediate arteries and 0.97 in the left circumflex. IVUS revealed jailed BVS struts with a minimum lumen area of 5.73 mm² at the carina site (A) and lumen area of 5.96 mm² distal to the carina site (B). BVS: bioresorbable vascular scaffold; FFR: fractional flow reserve; IVUS: intravascular ultrasound

How would I treat?

THE INVITED EXPERTS' OPINION

Ashok Seth*, FRCP, FACC, FESC, DSc; Gaurav Mohan, MD, DM; Vijay Kumar, MD, DNB

Fortis Escorts Heart Institute, New Delhi, India

This interesting case from Sato et al demonstrates the occurrence of an angiographically severe stenosis at the LAD ostium 12 months post-implantation of a BVS to treat an ostial proximal Cx stenosis when the BVS struts jailed the LAD ostium. The patient has some chest pain but no convincing objective evidence of ischaemia on non-invasive evaluation treadmill test (TMT).

It is well recognised that angiography is deceptive. In fact, the ostium of a jailed side branch can “look” dramatically worse due to impaired visualisation contributed to by incomplete blood/contrast mixing and image filtering/edge enhancement mismatch of digital angiography¹. Furthermore, at 12 months, the thick struts of BVS lying across the LAD ostium may develop neointimal tissue bridges², which could also worsen the angiographic appearance at the LAD ostium. As an OCT examination was not performed at the 12-month follow-up, this “real possibility” remains speculative. Thus, for us, the key to decision making is based on the intravascular physiology (FFR) and imaging (IVUS) data.

The FFR of 0.87 in the LAD and intermedius with intravenous adenosine hyperaemia clearly demonstrates good flow down both vessels. FFR >0.8 has been well proven to be associated with extremely favourable outcomes at follow-up on optimal medical therapy alone when compared to PCI³. While IVUS has only a moderate correlation for physiological significance and prognosis in non-left main

coronary lesions, an MLA >4.0 mm² (this patient's LAD ostium was measured at 5.73 mm²) identifies with reasonable accuracy non-significant lesions in which PCI can be safely deferred³. As 12 months have already elapsed since the index procedure, any further progression of ostial LAD and intermedius lesions from here on is unlikely. Furthermore, as the BVS resorbs by two to three years, there would be resolution of neointimal bridges, unjailing of the LAD ostia and positive remodelling of the vessels, all of which could lead to significant improvement of angiographic appearances at follow-up.

We would thus follow up this patient on optimal medical therapy. Keeping in mind the uncovered struts of BVS protruding in the left main, we would prefer to continue dual antiplatelet therapy till the BVS resorbs. We would perhaps perform non-invasive radionuclide perfusion imaging at two years post-index procedure and perform angiography, FFR and OCT at three years post-index procedure, by which time we would expect the BVS to be totally resorbed. We would “wait and watch” with keenness as “fresh knowledge and understanding” will come forth through such cases.

Conflict of interest statement

A. Seth is a member and consultant of the Absorb Global Clinical Advisory Board, Abbott Vascular, Santa Clara, CA, USA. The other authors have no conflicts of interest to declare.

*Corresponding author: Fortis Escorts Heart Institute, Okhla Road, New Delhi 110025, India.

E-mail: ashok.seth@fortishealthcare.com

How would I treat?

THE INVITED EXPERTS' OPINION

Alexandre Abizaid^{1*}, MD, PhD; J. Ribamar Costa Jr², MD, PhD

1. Invasive Cardiology Department, Instituto Dante Pazzanese, São Paulo, Brazil; 2. Coronary Intervention Section, Instituto Dante Pazzanese, São Paulo, Brazil

Sato et al present a very interesting and challenging case of progression of disease in the “jailed” ostium of a LAD after successful treatment of an ostial LCx lesion with an Absorb BVS one year earlier.

According to their description, the patient returned with mild to moderate symptoms of exertional angina (CCS II) and an inconclusive treadmill test, being referred for a repeat cinecoronariography, which showed patency of the Absorb BVS in the ostium and proximal LCx and a “severe”(?) lesion in the origin of the LAD and intermediate arteries. Functional invasive assessment (FFR) was performed which ruled out the presence of ischaemia both in the LCx and in the LAD or intermediate coronary arteries. Additional assessment with an invasive imaging modality (IVUS) showed an ostium of the LAD “jailed” by the scaffold but with a minimum lumen area of 5.73 mm². Based on the clinical history and angiographic, FFR and IVUS findings, the authors question how they should manage this case.

The presence of ischaemia still represents the “key element” in the decision-making process of patients with stable coronary disease. Studies with both non-invasive and invasive assessment of ischaemia have repeatedly demonstrated that patients with moderate to severe ischaemic burden usually have worse outcomes (death and non-fatal myocardial infarction) as compared to those individuals with none or mild ischaemia despite the angiographic findings³⁻⁶. In the present case, all three coronaries showed FFR values above 0.80, which rules out the presence of significant ischaemia and is a consistent predictor of favourable outcomes, at least in the midterm journey^{7,8}.

Of note, a discrepancy between visual lesion estimation and the presence of ischaemic obstructions is relatively frequent. In the FAME

trial, a significant number of angiographically significant stenoses were reclassified after FFR assessment. In this particular case, the presence of a trifurcated left main trunk makes the visual assessment even more challenging. By the still pictures provided by the authors at follow-up (**Figure 2**), we notice a superposition of the LAD and the intermediate artery on one view (**Figure 2C**), and the presence of 50 to 60% lesion on the ostium of the LAD on the “spider” view, despite the foreshortening of this projection (**Figure 2D**). Therefore, according to the available pictures, we are not totally convinced about the “severity” of the ostial LAD lesion as stated by the authors.

This patient has also undergone invasive imaging assessment with intravascular ultrasound at follow-up. It is important to state that the ideal IVUS “cut-off” value to treat (or not) an intermediate coronary lesion remains unclear and is subject to a lot of criticism due to the tendency of this imaging modality to overestimate lesion severity and induce unnecessary revascularisation procedures. The initial studies with IVUS pointed to a value of 4.0 mm² as the limit to decide on the need to revascularise a coronary lesion. Contemporary studies have suggested lower “cut-off” values (as low as 2.0 to 2.4 mm²), which might also vary according to lesion location (proximal vs. distal coronary segments). **Table 1** summarises the main studies on this topic. However, despite the criticism in terms of finding a “number” to justify the treatment, the literature is unanimous in pointing out the safety of IVUS in deferring revascularisation in patients with minimum lumen area larger than 4.0 mm², as in the current scenario.

Furthermore, IVUS gave very interesting and potentially useful information in this case: most of the lumen restriction in the ostium of the LAD is secondary to its entrapment by the LCx Absorb BVS,

*Corresponding author: Invasive Cardiology Department, Av. Dr. Dante Pazzanese, 500, Vila Mariana, São Paulo, SP, CEP 04012-180, Brazil. E-mail: aabizaid@uol.com.br

Table 1. Studies comparing intravascular ultrasound (IVUS) to functional assessment (non-invasive and invasive) in intermediate lesions.

	Abizaid et al ⁹	Nishioka et al ¹⁰	Briguori et cols ¹¹	Takagi et al ¹²	Kang et al ¹³	Ben-Dor et al ¹⁴	Waksman et al (FIRST trial) ¹⁵	Stone et al (VERDICT Pilot and FIRST) trials*
Comparator	CFR	MIBI	FFR	FFR	FFR	FFR	FFR	FFR
	112	70	53	51	201	92	367	303/241 (total=544)
Reference vessel diameter, mm	≥2.75 <3.5	N/I	N/I	≥2.5 <3.5	>2.5	≥2.5	≥2.5	≥2.5 <4.0 (Pilot) ≥2.75 <4.0 (FIRST)
IVUS "cut-off" value for MLA, mm ²	≥4.0	≤4.0	≤4.0	<3.0	<2.4	3.2	<3.07 (overall) <2.4 (vessels <3.0) <2.7 (vessels 3.0- 3.5) <3.6 (vessels > 3.5)	2.9
Accuracy, %	89	N/I	79	90.2	68	74	66	66
Sensitivity, %	N/A	90	92	83	90	69.2	64	66.3
Specificity, %	N/A	88	56	92.3	60	68.3	64.9	65.9

CFR: coronary flow reserve; FFR: fractional flow reserve; IVUS: intravascular ultrasound; MLA: minimum lumen area; N/A: data not available;
*Unpublished data (presented at TCT 2012). Additional to greyscale IVUS, this trial also used radiofrequency IVUS (Virtual Histology™), which failed to improve greyscale IVUS accuracy to identify intermediate lesions provocative of ischaemia.

which will soon “vanish away” and might result in late enlargement of this area. Of course, our current understanding of bioresorbable technology is relatively limited and it might, for instance, happen that, in the final stages of the bioresorption, the inflammation produced by the process might aggravate the adjacent LAD lesion. However, at present, this is just speculation and should not substantiate the difficult decision whether to intervene in this patient.

Therefore, in a simple way, our best answer would be the following. For now, keep the patient under optimal medical therapy,

but follow him carefully with non-invasive tests (scintigraphy and stress echo are the best options in this case).

Funding

The Instituto Dante Pazzanese has received a research grant from Abbott Vascular.

Conflict of interest statement

The authors have no conflicts of interest to declare.

How did I treat?

ACTUAL TREATMENT AND MANAGEMENT OF THE CASE

Though an angiogram in the right anterior oblique caudal view showed severe stenosis at the left anterior descending artery (LAD) ostium, we elected to defer intervention in view of the negative fractional flow reserve (FFR) result. Aggressive medical therapy and follow-up coronary angiography in two years was the recommended treatment plan.

Previous studies¹⁶⁻¹⁸ have demonstrated that angiographic or intravascular ultrasound-based decision making for the treatment of side branch (SB) stenosis after main branch crossover stenting may frequently lead to unnecessary procedures. Therefore, functional assessment with post-stenting FFR has been recommended as a guide for the treatment of angiographically “jailed” side branches. Despite a recent study¹⁹ showing only a weak correlation between diameter stenosis and functional significance, treatment of angiographically significant SB lesions post-stent (scaffold) implantation in the main branch remains a matter of debate. Clinical, angiographic and imaging follow-up of side branches jailed by a bioresorbable vascular scaffold (BVS) are of particular interest, given that scaffold struts at the orifice of the side branch can be bioresorbed and/or form a neointimal bridge/membrane². The OCT study arm of the ABSORB cohort B trial demonstrated that the SB ostium area free from BVS struts reached a nadir at 12 to 24 months after BVS implantation. Subsequently, and up to 36 months of follow-up, the strut-free area increased significantly due to absorption of the polymer backbone.

In the current case, the procedure was performed 12 months after index PCI, a timeframe which coincides with the nadir in the lumen area of the SB ostium area free of BVS struts. Furthermore, despite angiographic appearance suggestive of a significant ostial LAD lesion, functional assessment ruled out haemodynamic significance. Is it justified then to wait for the absorption of the BVS struts, which would theoretically lead to an increased SB ostium strut-free area?

Conflict of interest statement

The authors have no conflicts of interest to declare.

References

- Escaned J, Koo BW. Functional guidance with FFR: an effective and safe way to simplify percutaneous treatment of coronary bifurcations. *EuroIntervention*. 2012;7:1129-31.
- Okamura T, Onuma Y, García-García HM, Regar E, Wykrzykowska JJ, Koolen J, Thuesen L, Windecker S, Whitbourn R, McClean DR, Ormiston JA, Serruys PW; ABSORB Cohort B Investigators. 3-Dimensional optical coherence tomography assessment of jailed side branches by bioresorbable vascular scaffolds: a proposal for classification. *JACC Cardiovasc Interv*. 2010;3:836-44.
- Lotfi A, Jeremias A, Fearon WF, Feldman MD, Mehran R, Messenger JC, Grines CL, Dean LS, Kern MJ, Klein LW; Society of Cardiovascular Angiography and Interventions. Expert consensus statement on the use of fractional flow reserve, intravascular ultrasound, and optical coherence tomography: a consensus statement of the Society of Cardiovascular Angiography and Interventions. *Catheter Cardiovasc Interv*. 2014;83:509-18.
- Hachamovitch R, Hayes SW, Friedman JD, Cohen I, Berman DS. Comparison of the short-term survival benefit associated with revascularisation compared with medical therapy in patients with no prior coronary artery disease undergoing stress myocardial perfusion single photon emission computed tomography. *Circulation*. 2003;107:2900-7.
- Shaw LJ, Berman DS, Maron DJ, Mancini GB, Hayes SW, Hartigan PM, Weintraub WS, O'Rourke RA, Dada M, Spertus JA, Chaitman BR, Friedman J, Slomka P, Heller GV, Germano G, Gosselin G, Berger P, Kostuk WJ, Schwartz RG, Knudtson M, Veledar E, Bates ER, McCallister B, Teo KK, Boden WE; COURAGE Investigators. Optimal medical therapy with or without percutaneous coronary intervention to reduce ischemic burden: results from the Clinical Outcomes Utilizing Revascularization and Aggressive Drug Evaluation (COURAGE) trial nuclear substudy. *Circulation*. 2008;117:1283-91.
- Bech GJ, Pijls NH, De Bruyne B, Peels KH, Michels HR, Bonnier HJ, Koolen JJ. Usefulness of fractional flow reserve to predict clinical outcome after balloon angioplasty. *Circulation*. 1999;99:883-8.
- Tonino PA, De Bruyne B, Pijls NH, Siebert U, Ikeno F, van't Veer M, Klauss V, Manoharan G, Engström T, Oldroyd KG, Ver Lee PN, MacCarthy PA, Fearon WF; FAME Study Investigators. Fractional flow reserve versus angiography for guiding percutaneous coronary intervention. *N Engl J Med*. 2009;360:213-24.
- De Bruyne B, Pijls NH, Kalesan B, Barbato E, Tonino PA, Piroth Z, Jagic N, Möbius-Winkler S, Rioufol G, Witt N, Kala P, MacCarthy P, Engström T, Oldroyd KG, Mavromatis K,

Manoharan G, Verlee P, Frobert O, Curzen N, Johnson JB, Jüni P, Fearon WF; FAME 2 Trial Investigators. Fractional flow reserve-guided PCI versus medical therapy in stable coronary disease. *N Engl J Med*. 2012;367:991-1001.

9. Abizaid A, Mintz GS, Pichard AD, Kent KM, Satler LF, Walsh CL, Popma JJ, Leon MB. Clinical, intravascular ultrasound, and quantitative angiographic determinants of the coronary flow reserve before and after percutaneous transluminal coronary angioplasty. *Am J Cardiol*. 1998;82:423-8.

10. Nishioka T, Amanullah AM, Luo H, Berglund H, Kim CJ, Nagai T, Hakamata N, Katsushika S, Uehata A, Takase B, Isojima K, Berman DS, Siegel RJ. Clinical validation of intravascular ultrasound imaging for assessment of coronary stenosis severity: comparison with stress myocardial perfusion imaging. *J Am Coll Cardiol*. 1999;33:1870-8.

11. Briguori C, Anzuini A, Airolidi F, Gimelli G, Nishida T, Adamian M, Corvaja N, Di Mario C, Colombo A. Intravascular ultrasound criteria for the assessment of the functional significance of intermediate coronary artery stenoses and comparison with fractional flow reserve. *Am J Cardiol*. 2001;87:136-41.

12. Takagi A, Tsurumi Y, Ishii Y, Suzuki K, Kawana M, Kasanuki H. Clinical potential of intravascular ultrasound for physiological assessment of coronary stenosis: relationship between quantitative ultrasound tomography and pressure-derived fractional flow reserve. *Circulation*. 1999;100:250-5.

13. Kang SJ, Lee JY, Ahn JM, Mintz GS, Kim WJ, Park DW, Yun SC, Lee SW, Kim YH, Lee CW, Park SW, Park SJ. Validation of intravascular ultrasound-derived parameters with fractional flow reserve for assessment of coronary stenosis severity. *Circ Cardiovasc Interv*. 2011;4:65-71.

14. Ben-Dor I, Torguson R, Gaglia MA Jr, Gonzalez MA, Maluenda G, Bui AB, Xue Z, Satler LF, Suddath WO, Lindsay J, Pichard AD, Waksman R. Correlation between fractional flow reserve and intravascular ultrasound lumen area in intermediate coronary artery stenosis. *EuroIntervention*. 2011;7:225-33.

15. Waksman R, Legutko J, Singh J, Orlando Q, Marso S, Schloss T, Tugaoen J, DeVries J, Palmer N, Haude M, Swymelar S, Torguson R. FIRST: Fractional Flow Reserve and Intravascular Ultrasound Relationship Study. *J Am Coll Cardiol*. 2013;61:917-23.

16. Kang SJ, Ahn JM, Kim WJ, Lee JY, Park DW, Lee SW, Kim YH, Lee CW, Park SW, Park SJ. Functional and morphological assessment of side branch after left main coronary artery bifurcation stenting with cross-over technique. *Catheter Cardiovasc Interv*. 2014;83:545-52.

17. Naganuma T, Latib A, Costopoulos C, Takagi K, Naim C, Sato K, Miyazaki T, Kawaguchi M, Panoulas VF, Basavarajiah S, Figini F, Chieffo A, Montorfano M, Carlino M, Colombo A. The role of intravascular ultrasound and quantitative angiography in the functional assessment of intermediate coronary lesions: correlation with fractional flow reserve. *Cardiovasc Revasc Med*. 2014;15:3-7.

18. Koo BK, Kang HJ, Youn TJ, Chae IH, Choi DJ, Kim HS, Sohn DW, Oh BH, Lee MM, Park YB, Choi YS, Tahk SJ. Physiologic assessment of jailed side branch lesions using fractional flow reserve. *J Am Coll Cardiol*. 2005;46:633-7.

19. Ahn JM, Lee JY, Kang SJ, Kim YH, Song HG, Oh JH, Park JS, Kim WJ, Lee SW, Lee CW, Kim JJ, Park SW, Park SJ. Functional assessment of jailed side branches in coronary bifurcation lesions using fractional flow reserve. *JACC Cardiovasc Interv*. 2012;5:155-61.

Online data supplement

Moving image 1. Final angiogram at index percutaneous coronary intervention. Right anterior oblique, caudal view.

Moving image 2. Final angiogram at index percutaneous coronary intervention. Left anterior oblique, caudal view.

Moving image 3. 12-month follow-up angiogram demonstrating the narrowing of the left anterior descending artery ostium. Right anterior oblique, caudal view.

Moving image 4. 12-month follow-up angiogram demonstrating the narrowing of both the left anterior descending artery and the intermediate artery ostium. Left anterior oblique, caudal view.