

# Importance of confirmation by instant stent-accentuated three-dimensional optical coherence tomography during bifurcation stenting: far distal rewiring of iSA3D-OCT

Fumiaki Nakao\*, MD, PhD

Department of Cardiology, Yamaguchi Grand Medical Center, Yamaguchi, Japan

This paper also includes accompanying supplementary data published online at: [http://www.pconline.com/asiaintervention/1st\\_issue/12](http://www.pconline.com/asiaintervention/1st_issue/12)

## Description

An 83-year-old man with effort angina was admitted for percutaneous coronary intervention due to a stenosis in the ostial left anterior descending artery (LAD). After predilatation, the left main LAD was stented with a 3.5×24 mm 2-link biolimus-eluting stent (Nobori™; Terumo, Tokyo, Japan). After proximal optimisation technique and rewiring to the left circumflex artery, the distal rewiring was confirmed by two-dimensional modalities (**Figure 1A**). Instant stent-accentuated three-dimensional optical coherence tomography (iSA3D-OCT) was reconstructed in about 30 s from OCT (Dragonfly™ JP; St. Jude Medical, St. Paul, MN, USA) by ImageJ v1.47 (National Institutes of Health, Bethesda, MD, USA) with self-made macro programs. According to intraprocedural iSA3D-OCT, the recrossed wire passed through the far distal cell limited the expansion by the link (**Figure 1B, Moving image 1**).

Kissing balloon dilatation was performed by simultaneously inflating 3.5×15 mm balloons. Final iSA3D-OCT showed floating struts and struts covering sparsely (**Moving image 2**). A large centre cell rewiring might have been better, even if a metallic carina was made.

Distal rewiring confirmed by two-dimensional modalities may not lead to favourable results in some cases. Confirmation of a rewiring cell by intraprocedural iSA3D-OCT is important to find such cases.

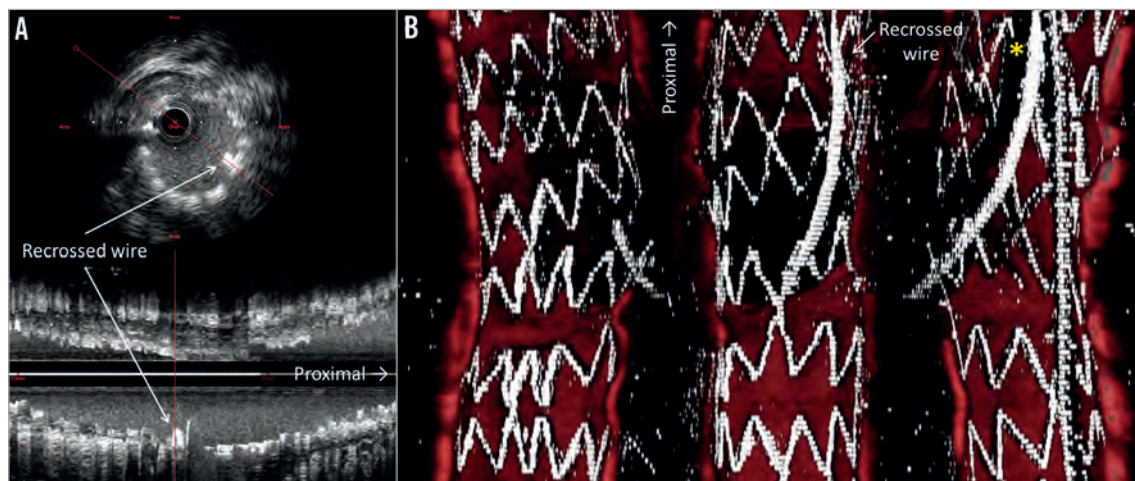
## Conflict of interest statement

The author has no conflicts of interest to declare.

## Online data supplement

**Moving image 1.** iSA3D-OCT after rewiring.

**Moving image 2.** iSA3D-OCT after kissing balloon dilation.



**Figure 1.** Intravascular ultrasonography showing distal rewiring (A) and iSA3D-OCT showing rewiring through far distal cell limited expansion by link (B). Asterisk (in top right corner) indicates guidewire shadow artefact.

\*Corresponding author: Department of Cardiology, Yamaguchi Grand Medical Center, 77 Ohsaki, Hofu, Yamaguchi, 747-8511, Japan. E-mail: [nakao-ymghp@umin.ac.jp](mailto:nakao-ymghp@umin.ac.jp)